Case Report

Archives of Clinical & Experimental Surgery

Complete Healing of the Diabetic Ulcerative Osteomyelitis with Atherectomy and Flexible Stent

Veysel Temizkan [1], Murat Ugur [1], Gokhan Arslan [1], Alper Ucak [1], Arif Selcuk [1], Oral Oncul [2], Ahmet Turan Yılmaz [1]

Abstract

Diabetes mellitus is a chronic disease that causes arterial and neurological disorders. Extremities threatening a diabetic foot ulcer might occur in the long term, especially in irregular glycemia levels. A multidisciplinary approach including infection treatment, pressure relief in the wound and arterial revascularization is important for limb salvage and to prevent such life-threatening complications as septicemia. Compared to the surgery, endovascular procedures can be performed with low complication rates in diabetic foot ulcers complicated with infection. Atherectomy is an alternative to the classical percutaneous angioplasty techniques, especially in totally occluded lesions. We are reporting complete healing of osteomyelitis associated with critical limb ischemia, resistant to classical treatment with debridement, antibacterial therapy and hyperbaric oxygen therapy, by atherectomy following long-segment flexible stent implantation.

Key words: *Diabetic foot, arterial stenosis, atherectomy, stent implantation*

[1] Department of Cardiovascular Surgery Gulhane Military Medical Academy Haydarpasa Training Hospital Istanbul / Turkey

[2] Department of Infectious Disease Gulhane Military Medical Academy Haydarpasa Training Hospital Istanbul / Turkey

Received: June 13, 2012
Accepted: August 02, 2012
Arch Clin Exp Surg 2014;3:193-196
DOI: 10.5455/aces.20120802123704

Corresponding author:
Murat Ugur, MD
Department of Cardiovascular Surgery
Gulhane Military Medical Academy
Haydarpasa Training Hospital
Selimiye mah. Tıbbiye cad.
34668 Uskudar
Istanbul / Turkey
drmugur@gmail.com

Introduction

Critical limb ischemia is a clinical condition frequently seen in diabetic patients and which might result in amputation. Foot ulceration might occur in the 15% of diabetic patients and there be a lower extremity amputation rate with a 40-fold increase in these patients. The annual cost of diabetic foot–associated complications is ≥ $1 billion in the United States [1]. Successful management of these patients depends on a multidisciplinary team approach. Arterial revascularization, pressure relief over the ulcer, antibiotherapy according to the antibiogram, and glycemia regulation help healing of diabetic foot infection and reduce amputation rates [2]. Of all these procedures, the most important step to accelerate wound healing in the treatment of a diabetic ulcer is revascularization.

Endovascular methods might be preferred for revascularization in infected critical limb ischemia in order to avoid surgical risk. Plaque excision with atherectomy in the angiographic total occlusion lesions increases medium- and long-term patency rates [3]. Stenting after atherectomy is proposed in only flow-limiting dissection or residual stenosis [4].

We are reporting complete healing of diabetic osteomyelitis with atherectomy and long-segment stent implantation, which is persistent conventional treatment with antibiotherapy, debridement and hyperbaric oxygen (HBO) treatment.

Case Report

A 65-year-old male patient with insulin-dependent diabetes mellitus and hyperlipidemia history was admitted to our hospital with complaints of a rash and fever up to the ankle and an unhealed ulcer on the left toe for 4 months. The ankle brachial index (ABI) was measured as 0.8 in the right lower extremity and 0.6 on the left one at rest. There were findings of osteomyelitis in the 1st metatarsus, proximal phalanx and basis of distal phalanx in magnetic resonance imaging (MRI). Doripenem and HBO were performed according to a culture antibiogram, which revealed pseudomanas aeroginosa. Although hyperemia disappeared in his ankle after fifteen days of antibiotic regimen and HBO therapy, the ulcer didn't regress and MRI angiography revealed long-segment 70-80% stenosis in the left superficial femoral artery (SFA) and mid-portion occlusion in right SFA (Figure 1). Endovascular treatment was performed with these findings for avoiding surgical and general anesthesia risks due to persistent infection.

After angiographic examination with an antegrade approach to both femoral arteries, a totally occluded lesion in the right SFA was crossed over with total occlusion guidewire, and atherectomy with the SilverHawk Plaque Excision System (Ev3 Inc. Nathan Lane North Plymouth, MN) was performed (Figure 2A-C, Figure 3A). Then two monorail self-expandable stents (7 mm x 10 cm) were implanted in the SFA artery respectively and the procedure was ended after the balloon dilatation and control angiography (Figure 2D-E). After this procedure, two monorail self-expandable stents (7 mm x 10 cm) were implanted in the left SFA (Figure 3B-C).

After revascularization, antibiotherapy was continued with clindamycin and fusidic acid perorally for 45 days. The patient was discharged on the 5th postoperative day with palpable distal pedal pulses, with resting ABI 1.1 on the left and 1.0 on the right legs and a com-

Figure 1. Bilaterally lower limb arteries viewed in preoperative MR angiography.

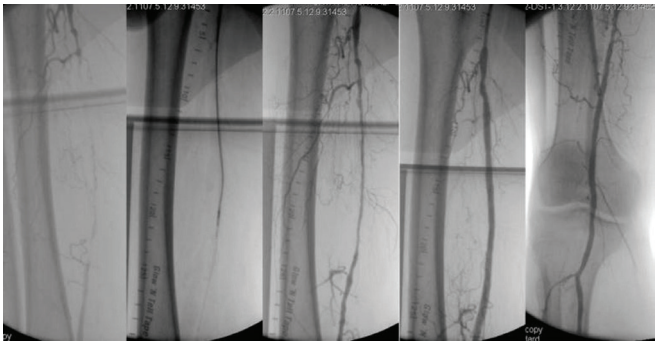

Figure 2. A. Long-segment total occlusion in right SFA in DSA. B. Plaque excision of right SFA with SilverHawk Plaque Excision System. C. Angiographic view of right SFA after plaque excision. D. Angiographic view of right SFA at the end of the procedure after stent implantation. E. DSA examination of popliteal and distal arteries after the procedure.

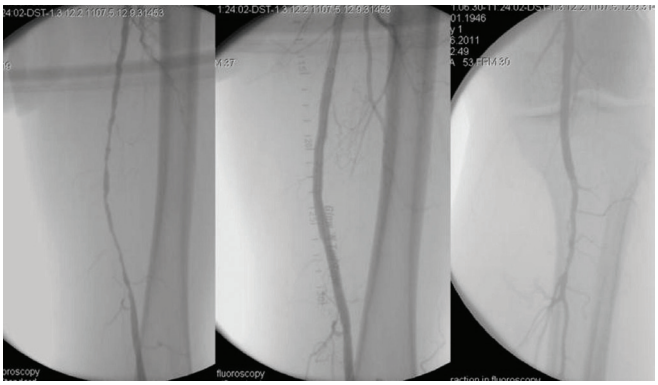

Figure 3. A. Evaluation of long-segment multisegmental stenosis in left SFA B. Angiographic view of left SFA at the end of the procedure. C. DSA examination of popliteal artery after the procedure.

Figure 4. View of completely healed diabetic ulcer.

pletely healed diabetic ulcer (Figure 4). Following the antibacterial therapy, the findings of osteomyelitis were controlled at the sixth month, and pedal pulses were palpable and stents were patent in Doppler ultrasonographic examination.

Discussion

Diabetic foot ulcer is a difficult-to-treat clinical condition which threatens the limb. The severity of the soft tissue infection, especially in the calcaneus area, accompanying osteomyelitis, pressure in the wound, and the impaired arterial circulation due to arterial stenosis are the affecting factors of the wound healing. The infection which starts at the heel area and the plantar flexor tendon level might rapidly expand and might cause development of cellulitis, gangrene and osteomyelitis [5]. Furthermore, it might cause amputation, septicemia and mortality. A multidisciplinary approach which includes the control of infection, diabetes regulation, and wound management (additional to arterial revascularization) increases limb salvage rates. We are reporting dramatic recovery of limb-threatening cellulitis, osteomyelitis and a diabetic ulcer resistant to conservative therapy, after atherectomy and long-segment stent implantation.

Endovascular procedures might be performed as the first-line therapy in critical limb ischemia, with a shorter healing period (due to avoiding surgical incision), less hospital staying time and low complication rates [6]. Alternative strategies become necessary because of 35% restenosis risk and low extremity-saving ratios in diffused long-segment lesions after angioplasty and stent implantation. To prevent restenosis-covered stents, medicated stents or atherectomy are suggested. Direct excision of plaque with atherectomy is a noteworthy technique that is performed, especially in totally occluded lesions [6,7]. Atherectomy techniques avoid stretch injury on arterial walls and the possibility of intimal hyperplasia development and smooth muscle cell proliferation. As a result, tearing, split, dissection and restenosis risks are lower [3,7].

In critical limb ischemia, atherectomy may be beneficial in the acute and long term, especially in the vessel diameter of 2-2.5 mm [8]. Direct atherectomy might be used with a 100% success rate in the early-term recanalization. Zeller et al. [5] applied atherectomy with an 86% technical success rate de novo or in native arterial restenosis or in-stent restenosis. Primary and secondary patency rates were 84% and 100% respectively in the de novo lesions, but this rate is worse in the restenosis (54% and 93% respectively). Also, in the subjects with half of them having critical limb ischemia, there was no need for minor/major amputation or surgical re-intervention in any of the patients [4,9]. Keeling et al. [9] reported 86% limb salvage with atherectomy in critical limb ischemia. Atherectomy can be performed with low perioperative risk without considering the transatlantic inter-society consensus (TASC) classification, or coexisting diseases such as hypertension and diabetes, but restenosis and reocclusion were higher in the 12-month follow-ups in severe arterial lesions according to the Rutherford classification system [6].

Dual antiplatelet treatment can be started three days prior to the atherectomy in order to avoid early-term restenosis. Regine et al. [6] applied heparine treatment, including the procedure day and the following two days, as a different method. We have also applied 300 mg of clopidogrel before the procedure and heparine perfusion for 6 hours after the procedure. Then we applied low molecular weight heparin (LMWH) for 3 days, in addition to dual antiplatelet treatment.

Zeller et al. [5] performed additional balloon dilatation in 24% and stent implantation in 6% after atherectomy for procedural success (≤30% residual stenosis). We have treated the diabetic leg ulcer associated with cellulitis and osteomyelitis with a multidisciplinary approach. Antibiotherapy and HBO treatment started as soon as the patient was consulted. Despite daily wound

care, debridement and conventional therapy, the wound didn't regress. We didn't perform surgery in the first attempt due to active infection. Although there was less than ≤ 50% residual stenosis after the atherectomy procedure, we performed flexible long-segment stent implantation for increasing blood flow. As a conclusion, diabetic wound without osteomyelitis completely healed in five days. Unlike previously reported articles [5,6], we performed long-segment stent implantation after atherectomy, and balloon dilatation is used after control angiography. Thus, we aimed to avoid potential embolic events and decrease usage of a contrast agent, also increasing inflow faster. In conclusion, the diabetic ulcer healed faster than we predicted. This is the first case in which a 20 cm stent implantation is used in a diabetic patient with a leg ulcer; a larger series is needed to make inference of long-segment stent implantation after atherectomy in diabetic patients.

Conclusion

A multidisciplinary approach is the principle of the treatment of critical limb ischemia. Endovascular interventions might be performed with the advantages of higher extremity rescue and survival rates for revascularization of these cases [10]. In totally occluded lesions, atherectomy is a reliable minimally invasive method with acceptable primary and secondary patency rates in critical limb ischemia [6]. Atherectomy following long-segment stent implantation might increase inflow and accelerate the period of wound healing.

Conflict of interest statement

The authors have no conflicts of interest to declare.

References

1. Faries PL, Teodorescu VJ, Morrissey NJ, Hollier LH, Marin ML. The role of surgical revascularization in the management of diabetic foot wounds. Am J Surg 2004;187(5A):34S-37S.
2. Boulton AJ. Pressure and the diabetic foot: clinical science and offloading techniques. Am J Surg 2004;187(5A):17S-24S.
3. Garcia LA, Lyden SP. Atherectomy for infrainguinal peripheral artery disease. J Endovasc Ther 2009;16(Suppl 2):105-115.
4. Treiman GS, Oderich GS, Ashrafi A, Schneider PA. Management of ischemic heel ulceration and gangrene: An evaluation of factors associated with successful healing. J Vasc Surg 2000;31:1110-1118.
5. Zeller T, Rastan A, Sixt S, Schwarzwälder U, Schwarz T, Frank U, et al. Long-term results after directional atherectomy of femoro-popliteal lesions. J Am Coll Cardiol 2006;48:1573-1578.
6. Regine R, Catalano O, De Siero M, Di Costanzo G, Ragozzino A. Endovascular treatment of femoropopliteal stenoses/occlusions with a SilverHawk directional atherectomy device: immediate results and 12-month follow-up. Radiol Med 2010;115:1208-1218.
7. Kolakowski S Jr, Calligaro KD, Dougherty MJ. Is infrainguinal percutaneous atherectomy better suited for certain arteries than others? Vasc Endovascular Surg 2009;43:462-466.
8. Zeller T, Sixt S, Schwarzwälder U, Schwarz T, Frank U, Bürgelin K, et al. Two-year results after directional atherectomy of infrapopliteal arteries with the SilverHawk device. J Endovasc Ther 2007;14:232-240.
9. Schmieder GC, Panneton JM. Endovascular superficial femoral artery treatment: can it be as good as bypass? Semin Vasc Surg 2008;21:186-194.
10. Dosluoglu HH, O'Brien-Irr MS, Lukan J, Harris LM, Dryjski ML, Cherr GS. Does preferential use of endovascular interventions by vascular surgeons improve limb salvage, control of symptoms, and survival of patients with critical limb ischemia? Am J Surg 2006;192:572-576.