

Giant Solitary Nodular Trichoepithelioma: A Case Report and Review of Literature

Sunder Goyal¹, Nanak Chand Mahajan², Monika Garg², Snigdha Goyal³

¹Department of Surgery,
Muzaffarnagar Medical College,
Muzaffarnagar, Uttar Pradesh,
INDIA

²Department of Pathology, MM
Institute of Medical Sciences and
Research, Mullana, Ambala,
Haryana, INDIA

³Department of Pathology, Dr
RML Post Graduate Institute
of Medical Sciences, New Delhi,
INDIA

Received: January 31, 2012

Accepted: February 17, 2012

Arch Clin Exp Surg 2012;1: 58-60

DOI: 10.5455/aces.20120217045444

Corresponding author

Sunder Goyal, MD

Department of Surgery

Muzaffarnagar Medical College,

Muzaffarnagar, Uttar Pradesh,

INDIA

drsfgoyal@yahoo.in

Abstract:

A giant solitary nodular trichoepithelioma (GST) is a rare trichogenic tumor, which may present as a pigmented lesion. A 45-year-old female was diagnosed as having a giant solitary nodular trichoepithelioma on her right forearm. About 11 cases have been reported in literature. Our case is the 2nd largest of all reported cases and, so far, GST of the forearm has not been reported in literature. The recognition of GST is important because of its close resemblance to basal cell carcinoma and other skin adnexal tumors, both clinically and histopathologically.

Keywords: Giant solitary trichoepithelioma, basal cell carcinoma, trichoepithelioma

Introduction

A giant solitary trichoepithelioma (GST) is a rare hair follicle tumor with mixed epithelial and mesenchymal proliferations, consisting of basaloid epithelial strands and cellular fibromyxoid stroma. It is a benign adnexal neoplasm and common sites comprise the face, head and neck, with rare occurrence at the perianal region. The gene involved in the familial form of trichoepithelioma is located on band 9p21.

An abnormality in this gene may result in one of three syndromes: Brooke-Spiegler syndrome, familial cylindromatosis, and multiple familial trichoepithelioma [1]. We can find about eleven reported cases in literature, [2] and there is not a single reported case of GST of the forearm. Our case is the 2nd largest of all GST cases reported so far.

Case report

A 45-year-old female presented with a slowly growing pigmented swelling on the right forearm of 25 years duration. The local examination revealed a pigmented swelling measuring 9.5×4×2.5 cm (Figure. 1). It was a firm, non-tender swelling present in the subcutaneous plane.

A small bleeding ulcer was present on the swelling. She presented in OPD due to bleeding. The general physical and systemic examinations were normal. There were no palpable lymph nodes in the right axilla. A clinical diagnosis of a soft tissue tumor was made. The whole of the tumor was excised. The tumor was sharply demarcated and was solid in consistency. It was nodular in nature. Tissue was sent for histopathology, which showed

stratified squamous epithelium underneath; there was a well-circumscribed tumor consisting of basophilic cells (Figure. 2). These cells were arranged in a lace-like pattern, occasionally forming a solid aggregate. These tumor islands showed peripheral palisading. There was presence of horn cysts of various sizes. The tumor was accompanied by hemorrhagic areas and was diagnosed as “trichoepithelioma.”

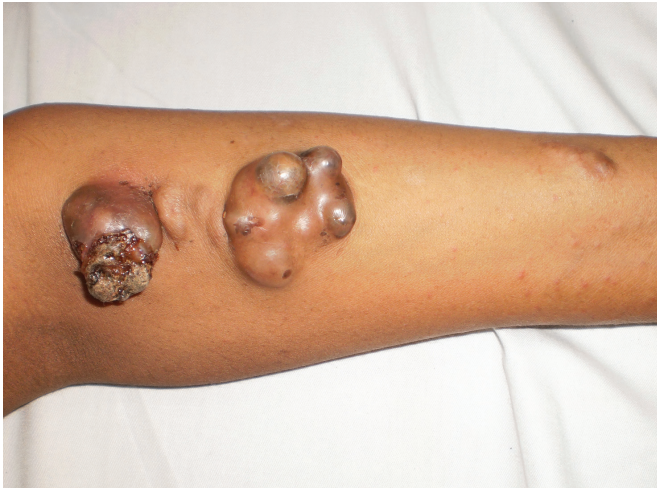

Figure 1. Giant Solitary nodular Trichoepithelioma of Forearm

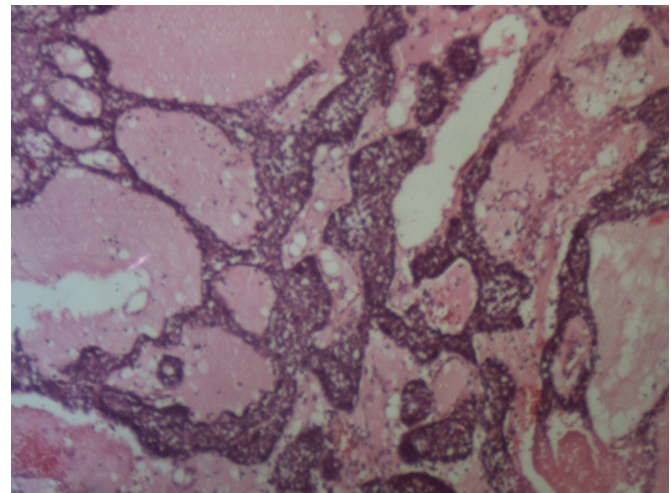


Figure 2. Figure shows nest and islands of basaloid cells (H&Ex100)

Discussion

Trichoepithelioma (also previously known as Epithelioma adenoides cysticum) is a trichogenic tumor described by Brooke in 1892 and later by Fordyce. It arises from the inferior segment of hair follicle epithelium. GST is a distinct variant of trichoepithelioma. It arises in elderly individuals and occurs

Table 1. Table showing clinical aspects of previously reported GST [2-6, 8-10].

Various Studies	Age in Years	Sex	Tumor Size in cm	Duration in Years	Site	Recurrence/Follow up
Czernobilsky B et al. 1972 [5]	58	M	8 (0)	20	R Thigh	None/?
Dvir E et al. 1981 [10]	70	M	2.5x1.5	?	Nose	None/1 year
Filho GB et al. 1984 [4]	53	M	6.5x4.5x3	3.5	R Thigh	None/9 months
Tatnall FM et al. 1986 [3]	77	F	3.5x3.5x2.5	7	Natal cleft	None/18 months
Tatnall FM 1986 [3]	71	M	5x3.5x2.5	Many	Buttock	None/1 year
Tatnall FM et al. 1986 [3]	70	F	3.5x2.5x2	10	Natal cleft	None/6 months
Beck S et al. 1988 [8]	31	M	2 (0)	-	Scrotum	Recurrence/17 years
Beck S et al. 1988 [8]	-	-	3 (0)	0.5	Scar	None/?
Oursin C. et al. 1991 [9]	67	F	17x8	15-20	Abdomen	None/?
Jemec C et al. 1999 [2]	48	M	4x2x1	?	L Shoulder	None/ 3.5 years
Krishnamurthy J et al. 2010 [6]	80	M	3x2	1	Right side of nose	None/?
Present case	45	F	9.5x4x2.5	25	Right Forearm	None/6 months

mostly on the face, thigh and peri-anal region [3,4]. It measures several centimeters in diameter. GST has been defined as a solitary trichoepithelioma with a diameter greater than 2 cm. [5]. These features are in contrast to the conventional trichoepithelioma, which presents as multiple small translucent circumscribed papules of 2–4 mm in diameter, in children and young adults. GST has a potential for local recurrence [6].

The majority of the GST has been subcutaneous, but pedunculated, ulcerated and cystic forms appear as well. The trichoepithelioma derives from the inferior segment of the follicle epithelium as a hamartoma. Three clinical forms of trichoepithelioma are recognized:

- a small solitary form
- a small multiple form, which is inherited in an autosomal dominant fashion
- a rare giant solitary form

Histologically, all three forms of trichoepithelioma are similar but not identical. They all show a well-demarcated tumor clearly differentiated as hair-forming structures [2].

GST presents as a pigmented lesion because of the increased activity of melanocytes or increased retention of pigments in the basal keratinocytes [7]. A giant solitary trichoepithelioma is a distinct variant of trichoepithelioma that may have a predilection for the perianal region. At this site, this rare tumor must be distinguished from basal cell carcinoma of the perineum and from malignant basaloid (cloacogenic) carcinoma of the anal canal [3].

Since trichoepithelioma is inherited in an autosomal dominant fashion, males and females receive the gene equally. Because of lessened expressivity and penetrance in men, most patients are women.

However, in various studies shown in Table 1 [2-6, 8-10], the M:F ratio of reported cases is 2:1; the age ranged between 31 and 77 years and the size varied between 2 cm and 17 cm.

Trichoepitheliomas are generally benign tumors and show slow growth, but in one of the only 11 published cases of the giant solitary form, recurrence after surgery has been described [8]. The rare cases of a trichoepithelioma described as having aggressive behavior, i.e. ulceration and recurrence, are probably follicular tumors within the basal cell nevus syndrome and not a trichoepithelioma. Thus, an increased clinical awareness as well as follow up therefore seems indicated in this rare neoplasm.

Conclusion

As a case of recurrence has been reported in literature, an increased clinical awareness as well as follow up is therefore mandatory in the GST neoplasm.

Conflict of interest statement

The authors do not declare any conflict of interest or financial support in this study.

References

1. Young AL, Kellermayer R, Szigeti R, Tészás A, Azmi S, Celebi JT. CYLD mutations underlie Brooke-Spiegler, familial cylindromatosis, and multiple familial trichoepithelioma syndromes. *Clin Genet* 2006;70:246-249.
2. Jemec B, Løvgreen Nielsen P, Jemec GB, Balsev E. Giant solitary trichoepithelioma. *Dermatol Online J*;1999;5:1.
3. Tatnall FM, Jones EW. Giant solitary trichoepitheliomas located in the perianal area: a report of three cases. *Br J Dermatol* 1986;115:91-99.
4. Filho GB, Toppa NH, Miranda D, Matos MP, da Silva AL. Giant solitary trichoepithelioma. *Arch Dermatol* 1984;120:797-798.
5. Czernobilsky B. Giant solitary trichoepithelioma. *Arch Dermatol* 1972;105:587-588.
6. Krishnamurthy J, Divya K. The cytology of giant solitary trichoepithelioma. *J Cytol* 2010;27:99-101.
7. Rosai J. Skin - Tumors and tumorlike conditions. In Rosai J (ed). *Rosai and Ackerman's Surgical Pathology*, Mosby Elsevier, St Louis, 2004;176.
8. Beck S, Cotton DW. Recurrent solitary giant trichoepithelioma located in the perianal area; a case report. *Br J Dermatol* 1988;118:563-566.
9. Oursin C, Krüger HJ, Sigmund G, Hellerich U. [MR imaging of a giant solitary trichoepithelioma of the skin]. [Article in German]. *Radiologe* 1991;31:574-576.
10. Dvir E. Solitary trichoepithelioma in a 70-year-old man. *Arch Dermatol* 1981;117:455-456.