Case Report

Archives of Clinical & Experimental Surgery

Transperitoneal Nephrectomy of Hydronephrotic Tubercular Kidney: A Rare Case Report

Sunder Goyal[1], Rajesh Aggarwal[2], Paramjeet Singh[2]

[1]Department of Surgery
Muzaffarnagar Medical College
Delhi-Dehradun Highway
Muzaffarnagar (UP), India

[2]Department of Urology
Deepak Hospital
Ludhiana, India

Received: May 08, 2012
Accepted: Jul 06, 2012
Arch Clin Exp Surg 2014;3:118-122
DOI:10.5455/aces.20120706044630

Corresponding author:
Dr. Sunder Goyal
Department of Surgery
Muzaffarnagar Medical College
Delhi-Dehradun Highway
Muzaffarnagar (UP), India
drslgoyal@yahoo.in

Abstract

Genitourinary tuberculosis (GUTB) is the second most common form of extrapulmonary tuberculosis, with more than 90% of cases occurring in developing countries. As tuberculosis causes complete destruction of the kidney, the giant hydronephrosis, due to tuberculosis, is a rare condition. Although the role of surgery in GUTB has decreased since the advent of anti-TB therapy, it can still have a role as an adjunct to drug treatment. A 65-year-old male presented with a huge abdomen. Clinical diagnosis of congenital pelvi-ureteric junction (PUJ) obstruction was made, and percutaneous nephrostomy was done to save the function of the kidney. Ultrasound and computed tomography (CT) confirmed the diagnosis. As it turned out to be a nonfunctioning kidney, transperitoneal laparoscopic nephrectomy was done. A histopathological report of the removed kidney revealed renal tuberculosis. Tubercular PUJ stricture presenting as giant hydronephrosis is uncommon; we thus present this case.

Key words: *Giant hydronephrosis, pelvi-ureteric junction obstruction, laparoscopy, nephrectomy*

Introduction

9.4 million new cases were reported in 2008, as tuberculosis is a global health problem. Developing countries have about 90% of cases [1]. Renal tuberculosis presenting as giant hydronephrosis is a rare urological entity because tuberculosis causes complete destruction and fibrosis of the renal unit. Renal TB is the frequent site of extra-pulmonary TB and its incidence is about 15-20% of all extra-pulmonary tuberculosis. Due to complex clinical features, management of renal TB is not easy. As TB has many clinical and radiological manifestations, diagnosis is usually delayed. Therefore, it is essential to have a high index of suspicion in mind for early detection and timely treatment to decrease the morbidity

[2]. Giant hydronephrosis is defined as the presence of more than 1000 ml of fluid in the collecting system. It can also be defined as a kidney that occupies the hemi-abdomen, which meets or crosses the midline and which is at least 5 vertebrae in length. A giant hydronephrotic kidney is mostly due to congenital pelvi-ureteric junction obstruction (PUJ) [3], but rarely being due to tubercular fibrotic stricture has also been reported in literature [4-6]. We present a rare case of a giant hydronephrotic kidney due to tubercular stricture managed with minimally invasive surgery.

Case Report

A 65-year-old male patient was admitted with huge abdominal swelling, which had been growing slowly for the last 5 years. There was only history of nausea and that was intermittent. There were no other signs and symptoms except for the feeling of heaviness. There was no relevant medical history like that of pulmonary or extra-pulmonary tuberculosis. The physical examination revealed a distended abdomen that was dull on percussion. All blood reports were within normal parameters. The patient was diagnosed with a cystic mass abdomen. On ultrasonography, the patient was diagnosed as a case of a cystic mass abdomen and probably gross hydronephrosis of the right kidney. Clinical diagnosis of hydronephrosis due to idiopathic congenital pelvi-ureteric junction obstruction was made. A CT scan confirmed the diagnosis of hydronephrosis of the right kidney (Figure 1). Percutaneous nephrostomy was done and about 1500 cc of fluid was drained in the bag. Subsequently, there was no urine formation from the kidney (non-functioning kidney); therefore, after 15 days, transperitoneal laparoscopic nephrectomy was done using four ports. The kidney could be dissected in spite of dense adhesions. A kidney specimen was sent for histopathological examination, which revealed caseating tubercular granuloma at PUJ (composed of epitheloid histocytes, lymphocytes and Langhan's multinucleated giant cells) (Figure 2). The patient was put on anti-tubercular chemotherapy. Aspirated fluid was never tested for Acid Fast Bacilli (AFB) because we never thought that tuberculosis could be the cause of giant hydronephrosis; the histopathological report was thus a surprise for the surgeon.

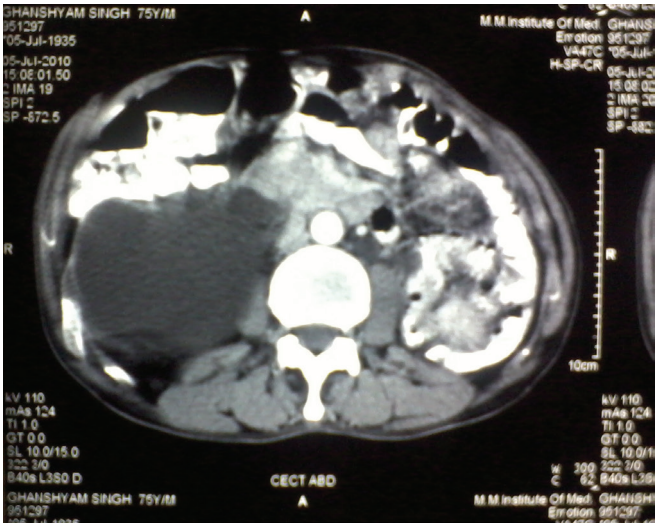

Figure 1. CT scan showing huge hydronephrosis of the right kidney.

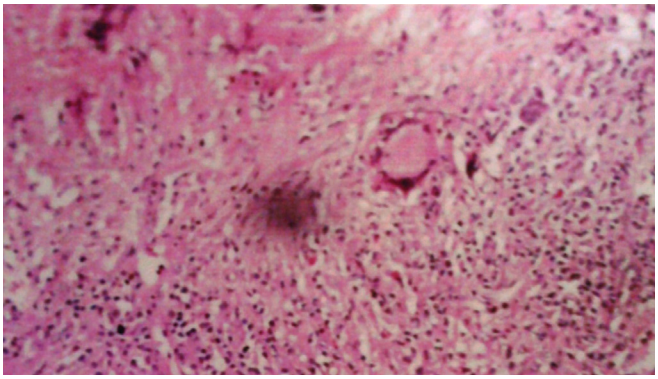
Figure 2. Histopathological slide showing Langhan's multinucleated giant cell, lymphocytes and epitheloid histocytes — a sign of renal tuberculosis.

Discussion

Renal TB is usually sequelae of pulmonary TB that had occurred at least 10-15 years earlier. The bacilli are usually lodged in the cortico-medullary region and form cortical granulomas. These granulomas remain dormant for many years. When the individual's immunity is threatened, there is a reactivation of these dormant bacilli, resulting in spread into the medulla and causing papillitis. The disease process is very slow, but as it progresses, it results in extensive necrosis of the renal papillae and may lead to the formation of frank cavities with abscess formation, ultimately resulting in total destruction of the renal parenchyma [2].

Tuberculosis affects any site in the urogenital system. Ureteral involvement in urinary TB is usually secondary to renal involvement. This usually occurs because of seeding of the ureter from the infected kidney [2]. James Gow, in his entire experience of genitor-urinary tuberculosis, has only seen 8 cases of pelvi-ureteric junction stricture caused by tuberculosis [6].

The most common cause of giant hydronephrosis is ureteropelvic junction obstruction.

Histopathologic analysis and urine culture are basic investigations to diagnose renal tuberculosis. Radiological examinations are useful supportive tools. Renal calcifications are one of the common manifestations of tuberculosis on a plain abdominal X-ray (in 24-44% of cases). Intravenous pyelography (IVP) is the most valuable investigation and may show a variety of findings, like moth-eaten calyces, amputated infundibula, hydronephrosis or hydronephroureter due to ureteral strictures and non-functioning of a kidney. Computed tomography (CT) is the most accurate modality to diagnose renal calcifications and may show the renal parenchymal cavity, mass and scarring, local parenchymal thinning, and stricture of infundibula. Computed tomography (CT) urography is now being increasingly used because it provides definite anatomic details of the pathology (comprehensive evaluation of both renal parenchyma and urothelium). It can also define the involvement of ureters and bladder. Magnetic resonance imaging (MRI) has limited value, but it is a useful imaging tool in defining the pathologic stages of renal tuberculosis. It can pick up abnormalities of a dilated collecting system, calyx and ureteral strictures independent of renal function. If there is no calcification in renal tuberculosis, only MRI can then confirm the diagnosis of renal tuberculosis because the tubercular nodule in the renal parenchyma had isointensity on T1-weighted images and low intensity on T2-weighted images without gadolinium enhancement [7]. Retrograde uretero-pyelography is mandatory for assessment of distal obstruction because it is important for reconstructive procedures [8].

Management of the hydronephrotic kidney depends upon the cause and on the number of kidneys involved. Ideally, percutaneous nephrostomy should be done as an initial procedure in all the patients (as done in our case) and then, based upon the overall functional status, ablation of the diseased kidney or reconstruction of the unit is done. Nephrectomy is the treatment of choice for a non-functioning kidney. Laparoscopic (transperitoneal/retroperitoneal) nephrectomy has a better result than open surgery, but in comparison, it takes a longer operative time. Despite the preference of a retroperitoneal approach in open urologic surgery, the transperitoneal approach is the globally preferred technique for laparoscopic urologic surgery [9].

Laparoscopic nephrectomy is difficult in infective renal diseases and tuberculous kidneys and was considered as a relative contraindication due to severe fibrotic adhesions between Gerota's fascia and the renal parenchyma with a higher conversion rate [10,11]. Recently with improved instrumentation and surgical skill, laparoscopic nephrectomy for a tuberculous kidney can be done with minimum perioperative and postoperative complications and with the same hospital stay as in laparoscopic nephrectomy for benign kidney diseases [12-19]. Laparoscopic nephrectomy for renal tuberculosis is a safe, effective, less invasive treatment modality and should be used as an initial approach.

The usual encountered difficulties during laparoscopic nephrectomy for a tuberculous kidney are due to dense adhesions with structures like the colon and inferior vena cava, which are liable to be injured during renal dissection. Dissection and ligation of renal vessels are very difficult due to perirenal dense adhesions. A hem-o-lock clip can be used for clamping the renal hilum vessels. During a transperitoneal approach, dense omental adhesions are encountered and there are chances of a mesocolic tear [15]. The transperitoneal approach permits better maneuverability of instruments than the retroperitoneal approach; however, the incidence of spillage of caseous material is higher in the peritoneal cavity with a transperitoneal approach. Laparoscopic retroperitoneal subcapsular nephrectomy can be done safely to remove an infected and heavily adhesive nonfunctional kidney, with minimal trauma, blood loss, and with faster recovery in comparison to open subcapsular nephrectomy [20]. In more difficult cases, the hand-assisted technique is used before converting to open surgery, aiming to preserve minimally invasive features in the treatment of inflammatory renal conditions [21]. Our case was a hydronephrotic kidney due to tubercular fibrotic stricture at PUJ and as there was no caseous destruction of the renal capsule, there were minimal adhesions and nephrectomy was easy. Laparoscopic nephrectomy was firstly successfully performed by Clayman in 1990 using the transperitoneal route. Later on, Gaur et al. described pure retroperito-

Table 1. Various studies in the literature with conversion rates.

Study	No. of Cases	Retro/Transperitoneal	Conversion
Gupta NP 1997 [10]	1	TP	0
Rassweiler J 1998 [11]	4/482	TP	4
Hemal AK 2000 [12]	9	RP	2
Kim HH 2000 [13]	13	9 TP - 4 RP	1
Lee KS 2002 [14]	31	TP	1
Chibber et al. 2002 [15]	8	TP	0
Xu Z 2004 [20]	12	RP (Subcapsular)	0
Zang X 2005 [17]	22	RP	0
Tobias-Machado M 2005 [21]	17	11 (RP) - 6 (TP hand-assisted)	0
Nagraj HK 2006 [18]	20/8 TB	TP	0
Cho HK 2008 [19]	39/11 TB	RP	0

neal access for nephrectomy by using a balloon to create the surgical working space. Table 1 shows various studies with conversion rates.

Conclusion

Our case shows that tuberculous nephrectomy can be done safely with no increased morbidity. There is no doubt that the mean operative time is more due to adhesions. The operating surgeon should be conscious about the various difficulties that he can come across. The transperitoneal approach allows good maneuverability of the instruments in difficult dissections, but the surgeon should be careful about chances of spillage in cases of tuberculous pyonephrosis. Nonfunctioning tuberculous kidneys can be removed laparoscopically, and the transperitoneal laparoscopic approach is as equally effective as retroperitoneal with no increased morbidity. But one should always be ready for laparoscopy-assisted open conversion whenever necessary.

Conflict of interest statement

The authors have no conflicts of interest to declare.

References

1. Treatment of Tuberculosis: Guidelines. World Healt Organization. WHO Press, Geneva, Switzerland, 2010.
2. Krishnamoorthy S, Gopalakrishnan G. Surgical management of renal tuberculosis. Indian J Urol 2008;24:369-375.
3. Shah SA, Ranka P, Dodiya S, Jain R, Kadam G. Giant hydronephrosis: What is the ideal treatment?. Indian J Urol 2004;20:118-122
4. Hong TU. [A Clinical observation of 15 cases of Giant hydronephrosis].[Article in Korean] Korean J Urol 1975;16:223-228.
5. Gupta H, Kone K, Pandey S, Dorairajan LN, Kumar S. Tubercular mass mimicking a tumour in a horseshoe kidney: a unique presentation. Int Urol Nephrol 2004;36:323-324.
6. Gow JG, Barbosa S. Genitourinary tuberculosis. A study of 1117 cases over a period of 34 years. Br J Urol 1984;56:449-455.
7. Matsui N, Morita T. Magnetic resonance imaging as a clue to successful diagnosis of renal tuberculosis: a case report. Cases J 2009;2:8879.
8. Cek M, Lenk S, Naber KG, Bishop MC, Johansen TE, Botto H, et al. Members of the Urinary Tract Infection (UTI) Working Group of the European Association of Urology (EAU) Guidelines Office. EAU guidelines for the management of genitourinary tuberculosis. Eur Urol 2005;48:353-362.
9. Quintela RS, Cotta LR, Neves MF, Abelha DL Jr, Tavora JE. Retroperitoneoscopic nephrectomy in benign pathology. Int Braz J Urol 2006;32:521-528.
10. Gupta NP, Agrawal AK, Sood S. Tubercular pyelonephritic nonfunctioning kidney--another relative contraindication for laparoscopic nephrectomy: a case report. J Laparoendosc Adv Surg Tech A 1997;7:131-134.
11. Rassweiler J, Fornara P, Weber M, Janetschek G, Fahlenkamp D, Henkel T, et al. Laparoscopic nephrectomy: the experience of the laparoscopy

working group of the German Urologic Association. J Urol 1998;160:18-21.
12. Hemal AK, Gupta NP, Kumar R. Comparison of retroperitoneoscopic nephrectomy with open surgery for tuberculous nonfunctioning kidneys. J Urol 2000;164:32-35.
13. Kim HH, Lee KS, Park K, Ahn H. Laparoscopic nephrectomy for nonfunctioning tuberculous kidney. J Endourol 2000;14:433-437.
14. Lee KS, Kim HH, Byun SS, Kwak C, Park K, Ahn H. Laparoscopic nephrectomy for tuberculous nonfunctioning kidney: comparison with laparoscopic simple nephrectomy for other diseases. Urology 2002;60:411-414.
15. Zhang X, Zheng T, Ma X, Li HZ, Li LC, Wang SG, et al. Comparison of retroperitoneoscopic nephrectomy versus open approaches to nonfunctioning tuberculous kidneys: a report of 44 cases. J Urol 2005;173:1586-1589.
16. Chibber PJ, Shah HN, Jain P. Laparoscopic nephroureterectomy for tuberculous nonfunctioning kidneys compared with laparoscopic nephroureterectomy for other diseases. J Laparoendosc Adv Surg Tech A 2005;15:308-311.
17. Nagraj HK, Kishore TA, Nagalakshmi S. Laproscopic nephrectomy for renal tuberculosis. Indian J Urol 2006;22:329-331.
18. Manohar T, Desai M, Desai M. Laparoscopic nephrectomy for benign and inflammatory conditions. J Endourol 2007;21:1323-1328.
19. Cho HK, Kim DS, Ryu DS, Oh TH, Jeon YS. Retroperitoneal Laparoscopic Nephrectomy for Inflammatory Renal Diseases. Korean J Urol 2008;49:107-112.
20. Xu Z, Xin M, Hong-Zhao L, Zhong C, Li LC, Ye ZQ. Retroperitoneoscopic subcapsular nephrectomy for infective nonfunctioning kidney with dense perinephric adhesions. BJU Int 2004;94:1329-1331.
21. Tobias-Machado M, Lasmar MT, Batista LT, Forseto PH Jr, Juliano RV, Wroclawski ER. Laparoscopic nephrectomy in inflammatory renal disease: proposal for a staged approach. Int Braz J Urol 2005;31:22-28.